



## Summary Feedback

(Combined feedback broadcasted at multiple times this week)

### PRE-RECORDED: Basildon FRCR 2B 'A to Zee' Course 2020

## Session 2/40

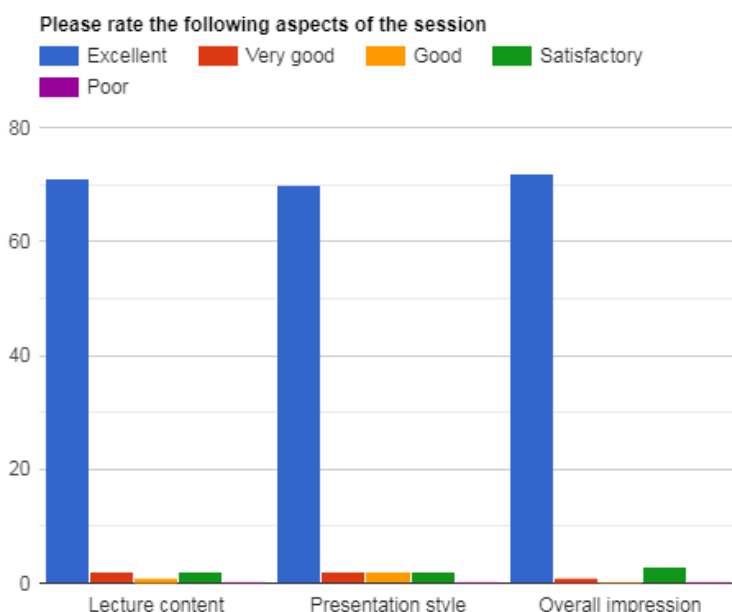
### Chest X-Ray For FRCR Exam (Part-2)

(11<sup>th</sup> and 12<sup>th</sup> May 2024)

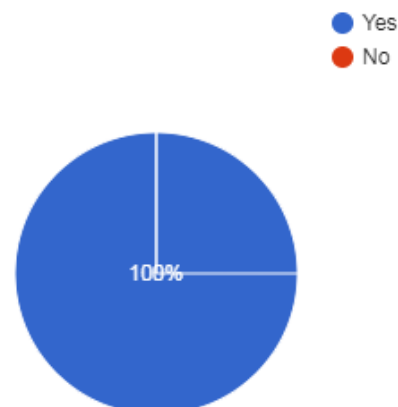
Lecturer: Thaj Rehman

#### Summary Points:

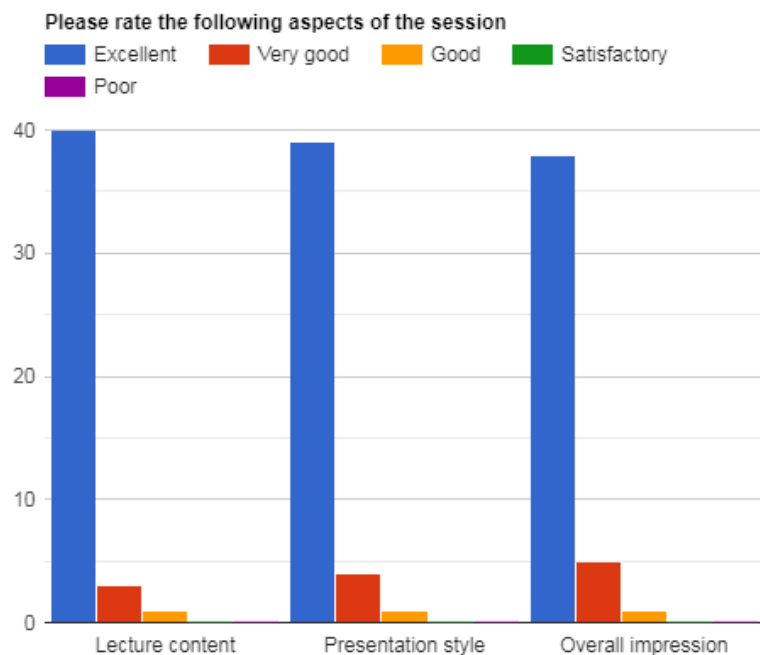
- Total Attendees: 408 from 37 Countries (Algeria, Australia, Bahrain, Bangladesh, Dominica, Egypt, Germany, Ghana, Hong Kong, India, Indonesia, Iran, Iraq, Jordan, Kenya, Malaysia, Malta, Myanmar, Nepal, Nigeria, Oman, Pakistan, Poland, Qatar, Saudi Arabia, Singapore, South Africa, Sri Lanka, Sudan, Swaziland, Türkiye, UAE, UK, Ukraine, Yemen, Zambia, Zimbabwe).
- Total duration: 2.5 hours (each session broadcasted thrice during the week)
- Total feedback received from 136 participants, from three different broadcasts



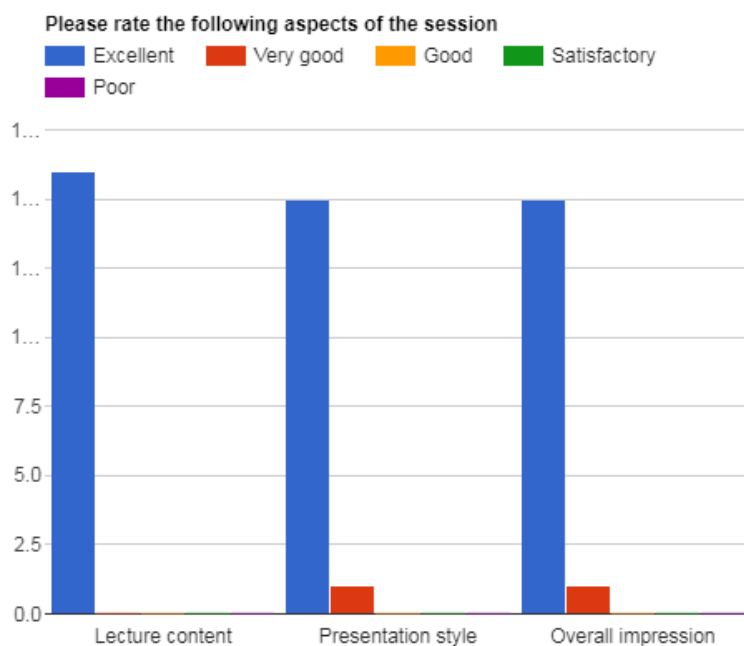
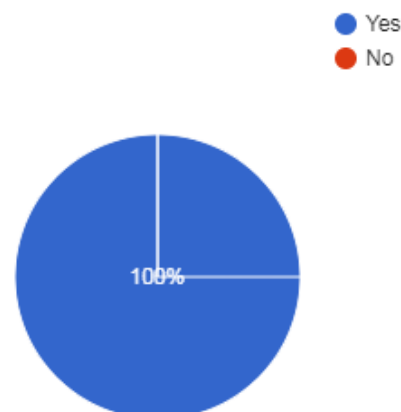
Did you find it useful  
76 responses



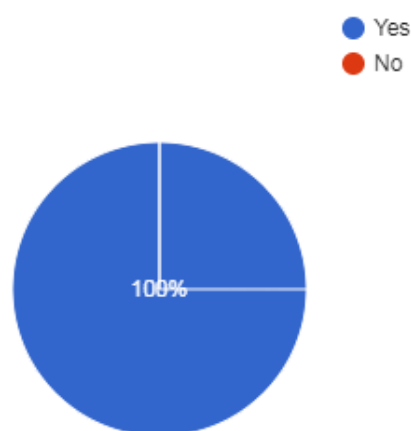
## CHEST X-RAY FOR FRCR EXAM (Part-2)



Did you find it useful  
44 responses



Did you find it useful  
16 responses



### Testimonials

- He is so good at portraying concepts and making explanations clear. The best CXR lectures I've seen yet anywhere! (UK).
- Very thorough explanation by Dr. Rehman. Different patterns of interstitial lung diseases along with alveolar opacities are well described. I learnt a lot. Thanks a lot (Pakistan).
- He has explained all concepts in detail including the basic concepts which no one actually teaches. Learnt a lot from this session (India).
- Excellent session delivered by Dr Thaj Rehman, very relevant exam cases. Grateful to team DKT! (Pakistan).
- All chest covered in 2 lectures, great cases, many concepts cleared (Pakistan).

## CHEST X-RAY FOR FRCR EXAM (Part-2)

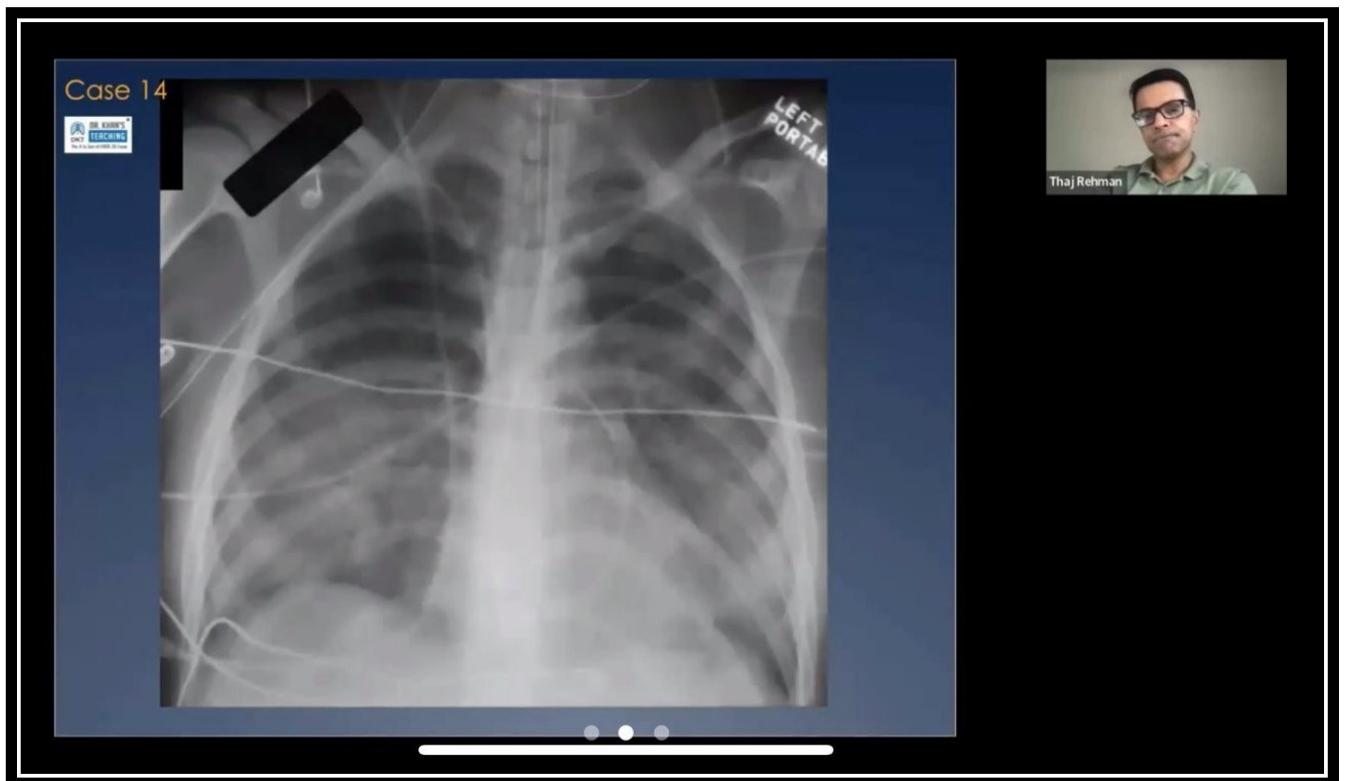
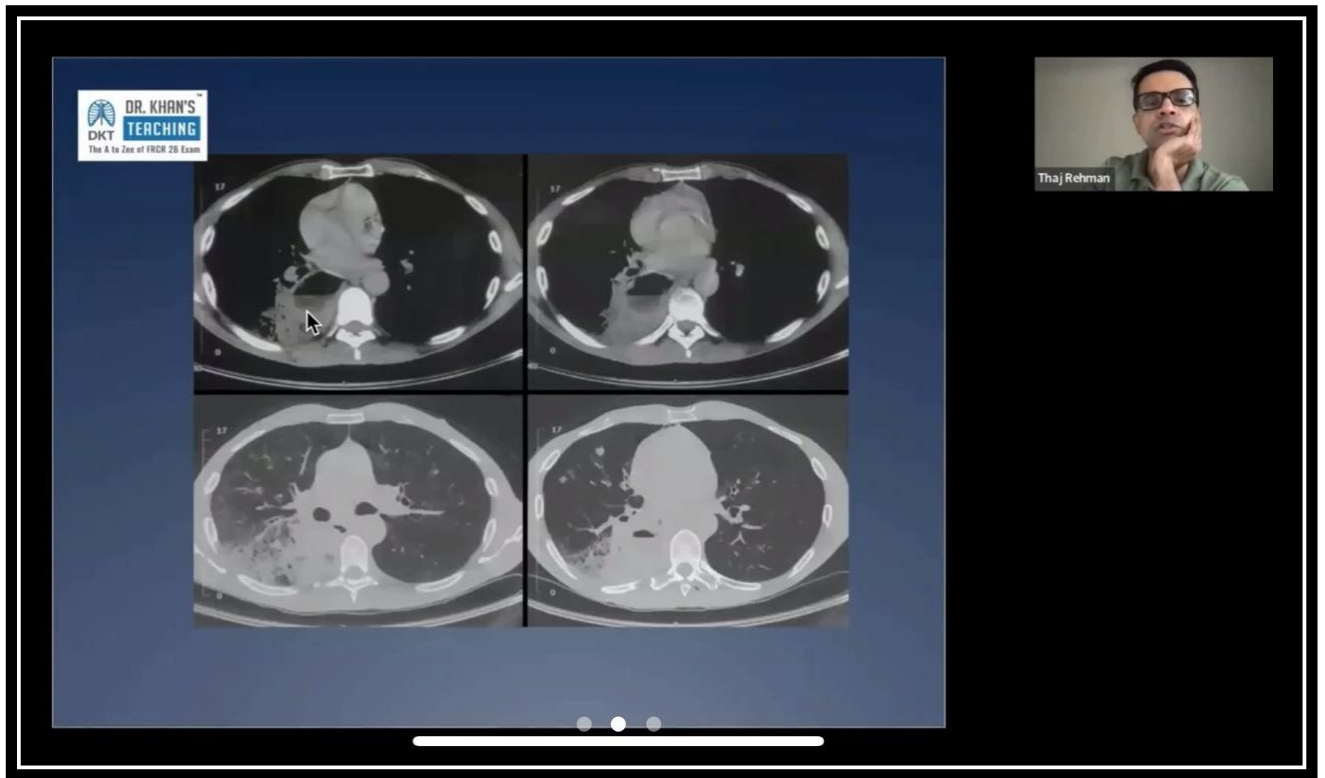- Covered all lung and mediastinal cases with good explanation (India).
- Very comprehensive lecture with great detail as well as exam oriented (India).
- It was perfect (UAE).
- I liked the cases and explanations. The terms and slides breaking down differentials were most useful. The cases were good and much needed (UK).
- I took this lecture in parts. thank you for repeating the lecture. Almost whole of chest radiology has been covered in these 2 classes (Pakistan).
- Very good learning experience (India).
- Excellent teaching session (Algeria).
- When you see reticulations next check out lung volume, hydatid and pluerofibroma were most useful (Zimbabwe).
- Difference between reticular and nodular shadowing with normal vascular pattern was most useful (Pakistan).
- The number of images used ensure exposure to different conditions was most useful (Zimbabwe).
- Excellent teaching as always (UK).
- Bronchiectasis and emphysema was most useful (Pakistan).
- Chest radiograph were most useful (Pakistan).
- Very nice and beneficial cases (UK).
- Great cases (UK).
- Content and delivery was most useful and valuable (UK).
- Interactive session (Pakistan).
- Differentials of each case was most useful (India).
- Helpful in daily reporting as well as helpful in making diagnosis of chest diseases (Pakistan).
- How to arrive to the diagnosis was most useful (Malaysia).
- Good explanation (UK).
- Focusing on one module specifically the hectic X-ray imaging was most useful (UAE).
- Excellent teaching (Malaysia).
- Interstitial and alveolar shadowing differentiated clearly (UK).
- Case discussion was most useful (India).
- Course content was excellent and covering exam oriented topics (India).
- Many Differential cases and interstitial lung disease was clarified (Pakistan).
- Discussion make points clearer was most useful (Pakistan).
- Different unusual cases were most useful (UAE).
- Good basics reinforcement (UAE).
- The variety of films was most valuable (Pakistan)
- Cases covering wide range of topics in X-ray chest were most useful (India).
- Very good cases and interpretation (UK).
- Image description and learning points were most useful (Nigeria).
- Very informative session with good exam cases and tips (Pakistan).
- Excellent lecture (India).
- Spectrum of cases was most useful (India).
- Variety of CXRs was most useful (Iraq).
- Case based teaching with clear excellent discussion based explanation (Egypt).
- It was perfect (UAE).
- Brilliant as always (Iraq).
- Interesting cases and constructive feedback was most useful (Algeria).
- Case collection was most useful (India).

## CHEST X-RAY FOR FRCR EXAM (Part-2)

- Explaining the basics of film reading was most useful (India).
- The clarity of explanations was most useful (UK).
- I liked the various diseases seen on chest X-ray (Pakistan)
- Cases and explanation was most useful (UK).
- Enhances knowledge and approach to chest X-ray interpretation (Pakistan).
- Amazing (UAE).
- Excellent cases (Saudi Arabia).
- Very useful (UK).
- Excellent (Pakistan).
- Brilliant session (Pakistan).
- Excellent (India).
- Excellent discussion (India).
- Discussion after each case was most useful (UK).
- X-ray teaching was most valuable (India).
- Nice cases (Pakistan).
- Chest radiograph were most useful (Pakistan).
- Variable diseases on chest X-ray were most useful (Pakistan).
- Excellent cases (UK).
- Great cases with systemic approach were most useful (Pakistan).
- Correlation of CXR with CT chest was most useful (Pakistan).
- Good cases and revision (India).
- All the aspects were useful (Saudi Arabia).
- Simplified lecture (India).
- Basic knowledge of X-ray interpretation was most useful (Pakistan).
- Skill of explanation and differentials was most useful (Sri Lanka).
- Content and delivery was most useful (UK).
- Those small points of identification for diseases were most useful (Pakistan).
- Cases were superb. Presentation was also very good (Pakistan).
- Teaching material and method was most useful (UAE).
- Rapid progression seen many cases were most useful (Malta).
- Appearance of the CXRs and the facts given were most useful (UK).
- Excellent teaching (Malaysia).
- The variety of cases and explanation style of presenter was most useful (Pakistan).
- Discussed many example cases with explanation was most useful (UK).
- Very interesting cases and excellent teaching (Sri Lanka).
- Great session (Pakistan).
- Very good lecture (UK).
- Excellent teaching (Pakistan).
- Excellent as always (Pakistan).
- Great (UK).
- Excellent teaching. Thank you (Malaysia).
- Exceptional (Pakistan).
- Impressive (Iraq).
- Excellent (Zimbabwe).
- Excellent description of chest X-ray pathologies (Pakistan).
- Clear the basic concept. Excellent session (Pakistan).
- Valuable teaching points (Pakistan).

## CHEST X-RAY FOR FRCR EXAM (Part-2)

- Nice learning (Pakistan).



# CHEST X-RAY FOR FRCR EXAM (Part-2)

Lengths of air fluid levels vary in lat v/s PA Xrays in hydro-pneumothorax

DR. ABDUL TEACHING

Thaj Rehman

=====XX=====XX=====